

# Pragmatic Management of Hand Involvement in Extended Oligoarticular Juvenile Idiopathic Arthritis: Ultrasound-guided Serial Interphalangeal Joint Injections

## Author(s)

İsa Cüce<sup>1</sup>, Rıdvan Yıldızhan<sup>1</sup>, Enes Veziroğlu<sup>2</sup>, Ayşenur Paç Kısaarslan<sup>3</sup>

## Affiliation(s)

<sup>1</sup>Erciyes University Faculty of Medicine, Department of Physical Medicine and Rehabilitation, Kayseri, Turkey

<sup>2</sup>Nevşehir State Hospital, Clinic of Physical Medicine and Rehabilitation, Nevşehir, Turkey

<sup>3</sup>Erciyes University Faculty of Medicine, Department of Pediatrics, Division of Pediatric Rheumatology, Kayseri, Turkey

## Article Information

Article Type: Case Report

Article Group: Pediatric Rheumatology

Received: 04.12.2022

Accepted: 21.02.2023

Available Online: 22.06.2023

**Cite this article as:** Cüce İ, Yıldızhan R, Veziroğlu E, Paç Kısaarslan A. Pragmatic Management of Hand Involvement in Extended Oligoarticular Juvenile Idiopathic Arthritis: Ultrasound-guided Serial Interphalangeal Joint Injections. *J Pediatr Acad* 2023; 4: 74-76

## Abstract

Small-joint involvement, including the interphalangeal joints of the hand, is less common in oligoarticular juvenile idiopathic arthritis (JIA). Ultrasound (US)-guided joint injections are also plausible for children. However, US-guided injections into pediatric small joints make the tips and tricks special because of the more difficult injection technique and greater risk of potential complications than with large joints. Here, we report the tips and tricks of serial US-guided interphalangeal joint injections in a male child with oligoarticular JIA who progressed to extended polyarthritis after an initial 6-month follow-up.

**Keywords:** Hand, interphalangeal joint, injection, ultrasound, juvenile idiopathic arthritis

## Introduction

The role of musculoskeletal ultrasound (US) in diagnosis and treatment decisions in juvenile idiopathic arthritis (JIA) is controversial in some areas. On the other hand, US guidance is now a necessary reality for almost all joint injections in children, similar to adults.<sup>1</sup> However, US-guided injections into pediatric small joints make the tips and tricks

special because of the more difficult injection technique and greater risk of potential complications compared with large joints, as well as the child's moodiness and/or possibly the limited experience of the clinician. Therefore, we report both our experience with the injection technique and protocol, and the patient's clinical outcomes after serial steroid injections into the interphalangeal (IP) joints.



**Correspondence:** İsa Cüce, Erciyes University Faculty of Medicine, Department of Physical Medicine and Rehabilitation, Kayseri, Turkey

**E-mail:** dr.icuce@hotmail.com **ORCID:** 0000-0002-1290-9540

## Case Report

A 12-year-old male who was followed up with the diagnosis of oligoarticular JIA was referred to our clinic for intra-articular corticosteroid (IAC) injection due to flare of synovitis in the IP joints of the hands. His complaints started four years ago with pain and swelling in the proximal IP (PIP) joint of the 2nd finger on the right hand. Antinuclear antibodies were also positive while rheumatoid factor was negative at the time of JIA diagnosis.

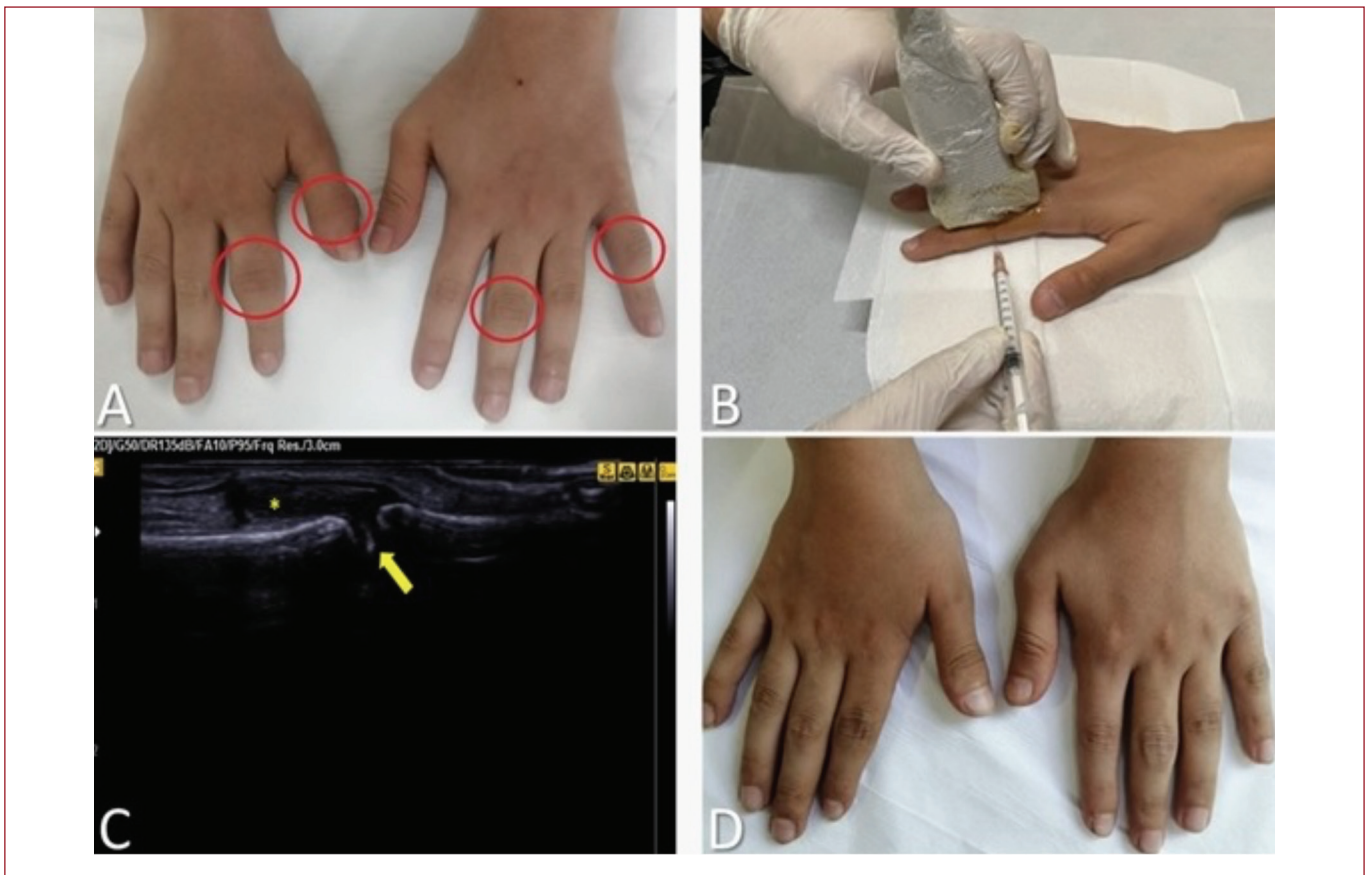
After the initial 6-month follow-up, synovitis developed progressively in the other small joints of the hand. He was then given methotrexate (subcutaneous, 15 mg weekly), naproxen (oral, 500 mg daily) and folic acid (oral, 5 mg twice weekly). However, there was exacerbation of synovitis in some joints of his hands 2 months ago.

On physical examination, there was swelling and mild tenderness in the IP joint of the 1st finger and PIP joint of the 2nd finger on the right hand, and the PIP joints of the 3rd and 5th fingers on the left hand (**Figure 1A**). Also, there were limitations in varying degrees of flexion range of motion in the affected joints. On the pain assessment, the mean numeric rating scale (NRS, 0-10) score for these joints was 6. Sonographic evaluation of both hands revealed active synovitis characterized by synovial effusion, synovial hypertrophy, and hypervascularity in the affected joints. Other than mild anemia, routine biochemistry and other laboratory tests including acute phase reactants were within normal limits.

US-guided IAC injection was planned for the affected joints of the patient. After getting written consent, the IP joint was visualized longitudinally on the dorsal side of the hand with US under sterile conditions. Then, the lateral side of the joint was entered using the out-of-plane technique with a 26G needle (**Figure 1B**). After the needle tip was seen in the joint, the appropriate dose of triamcinolone hexacetonide was injected into the joint (**Figure 1C**). The same procedure was repeated in the form of 2.5 mg triamcinolone hexacetonide injections at 1-month intervals for the other affected joints of the patient. No side effects were observed after the injections. The average NRS was 1 at the patient's 1-month evaluation after the last injection. The swelling resolved completely in 3 of the 4 swollen joints of the patient and partially resolved in one (**Figure 1D**). A 5-point Likert scale (1=very dissatisfied, 2=not satisfied, 3=none, 4=satisfied, and 5=very satisfied) was used to evaluate the overall satisfaction of the patient with the treatment. The patient evaluated his satisfaction after the serial injections as very satisfied (5).

## Discussion

Oligoarticular JIA mainly involves the lower extremity joints such as the knee and ankle. However, small-joint involvement, including the IP joints of the hand, is more rare.<sup>2</sup> Here, we present a male patient who slowly progressed to extended oligoarticular JIA, which is known as a poor prognosis criterion, after the first



**Figure 1.** **A)** Arthritis in the 1st finger IP and 2nd finger PIP joints on the right hand and the PIP joints of the 3rd and 5th fingers on the left hand (pre-injection). **B)** Position of the hand and US probe for US-guided PIP joint steroid injection, and the position of the needle for insertion into the joint with the out-of plane technique. **C)** US image of IP joint injection. Synovial hypertrophy and effusion (star); intra-articular steroid particles (arrow). **D)** Control at 1 month after serial injections. In the right hand, arthritis of the 1st finger IP, 2nd finger PIP and left hand 5<sup>th</sup> finger PIP joints healed completely, there was no swelling; partial improvement in the PIP joint of the 3rd finger on the left hand, slight swelling.

6 months of follow-up. Young children with prominent swellings on their hands may also experience more appearance-related stress. Our patient expressed this as “I will feel better if the swelling in my hands improves rather than pain”.

The patient we report here had only one joint involvement (PIP joint in the 2nd finger of the right hand) at the time of diagnosis. Other joint involvements developed progressively over the years. Because of this slow progression, IAC injections were administered before biological disease modifying anti-rheumatic drug treatments. IAC injections are a joint-targeted treatment option that provides rapid symptomatic and functional recovery in oligoarticular JIA and should be considered primarily for any joint involvement. In addition, a multicenter study revealed that concomitant use of methotrexate in patients may be associated with higher and longer efficacy for IAC.<sup>3</sup>

Although joint injections are widely performed in JIA, uncertainties remain regarding the technique, frequency of administration, which steroid to use and doses. The most preferred steroid for joint injections is the long-acting triamcinolone hexacetonide. Some authors recommend applying methylprednisolone acetate to small or difficult-to-assess joints because of the risk of subcutaneous atrophy and hypopigmentation.<sup>4,5</sup> However, Young et al.<sup>6</sup> reported the results of US-guided injection into small, medium, and large joints in patients with JIA, and applied triamcinolone hexacetonide or acetate to IP joints, and these side effects were reported in only 2.5% of all injections (localization unclear). US allows imaging of the needle tip as well as the distribution of the steroid within the joint. In addition, avoidance of excessive distension with the volume of the injected material (i.e., steroid) in small joints, absence of steroid contamination to the metal part or tip of the needle before injection, and immobilization after injection are among the safety measures.<sup>5,7</sup>

Another dilemma regarding joint injections in JIA is whether to give a single or multiple injections in one session. The most important limitations of multiple IAC injections are that it requires general anesthesia or sedation in most children, the prolongation of the procedure and follow-up time, and the increased risk of potential systemic side effects associated with higher total steroid dose.<sup>5,8</sup> Although the procedure compliance of our young child case was good, we performed a joint injection in one session because the technique of injection into the small joints was difficult and the patient did not want anesthesia or sedation. We then repeated the same procedure with an interval of 1 month. In the following sessions, it was observed that patient compliance with the procedure increased even more. This may be due to the dramatic improvement of pain and swelling after the first injection, and possibly due to verbal information given to the patient about the procedure with US images. Therefore, in our opinion,

individual injection planning in children with JIA may be a more accurate approach. A simplified injection protocol for multiple joints, as in this case, may be an alternative to the difficulties of multiple injections.

## Conclusion

In summary, IP joint injection can be safely performed in selected children with JIA under US guidance, without anesthesia or sedation. In addition, serial injections for delicate joints in patients resistant to conventional therapy may be an alternative to the difficulties and risks of multiple injections.

**Author Contributions:** All authors declare that they have participated in the design, execution, and analysis of the article and that they have approved the final version. Cüce İ: Concept, Design, Analysis or Interpretation, Literature Search, Writing.; Yıldızhan R: Concept, Analysis or Interpretation, Literature Search.; Veziroğlu E: Concept, Design, Analysis or Interpretation, Literature Search.; Paç Kisaarslan A: Concept, Writing.

**Conflict of Interest:** There are no conflicts of interest in connection with this paper. Also the material described is not under publication or consideration for publication elsewhere.

**Financial Disclosure:** The authors declared that this study has received no financial support.

**Informed Consent:** For this article and the pictures used in the article, the written consent was taken from the patient's parent.

## References

1. Cimaz R, Giani T, Caporali R. What is the real role of ultrasound in the management of juvenile idiopathic arthritis?. *Ann Rheum Dis.* 2020;79:437-439. [\[CrossRef\]](#)
2. Barut K, Adrovic A, Şahin S, et al. Juvenile Idiopathic Arthritis. *Balkan Med J.* 2017;34:90-101. [\[CrossRef\]](#)
3. Ravelli A, Davi S, Bracciolini G, et al. Intra-articular corticosteroids versus intra-articular corticosteroids plus methotrexate in oligoarticular juvenile idiopathic arthritis: a multicentre, prospective, randomised, open-label trial. *Lancet.* 2017;389:909-916. [\[CrossRef\]](#)
4. Scott C, Meiorin S, Filocamo G, et al. A reappraisal of intra-articular corticosteroid therapy in juvenile idiopathic arthritis. *Clin Exp Rheumatol.* 2010;28:774-781. [\[CrossRef\]](#)
5. Nieto-González JC, Monteagudo I. Intra-articular joint injections in juvenile idiopathic arthritis: state of the art. *Reumatol Clin (Engl Ed).* 2019;15:69-72. [\[CrossRef\]](#)
6. Young CM, Shiels WE 2nd, Coley BD, et al. Ultrasound-guided corticosteroid injection therapy for juvenile idiopathic arthritis: 12-year care experience. *Pediatr Radiol.* 2012;42:1481-1489. [\[CrossRef\]](#)
7. Cahill AM, Cho SS, Baskin KM, et al. Benefit of fluoroscopically guided intraarticular, long-acting corticosteroid injection for subtalar arthritis in juvenile idiopathic arthritis. *Pediatr Radiol.* 2007;37:544-548. [\[CrossRef\]](#)
8. Batu ED. Glucocorticoid treatment in juvenile idiopathic arthritis. *Rheumatol Int.* 2019;39:13-27. [\[CrossRef\]](#)